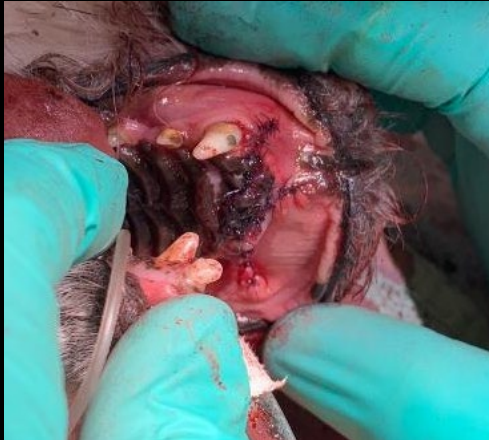

A VetCAT CT scan was taken to help guide treatment decisions.

Maddie

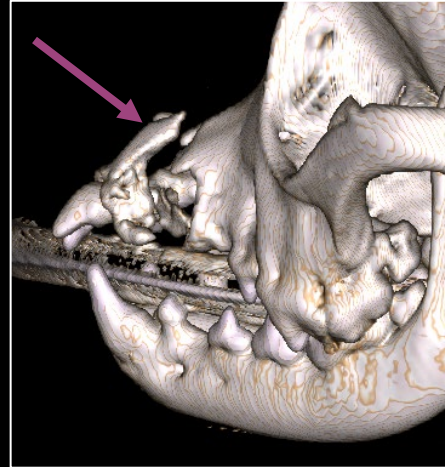
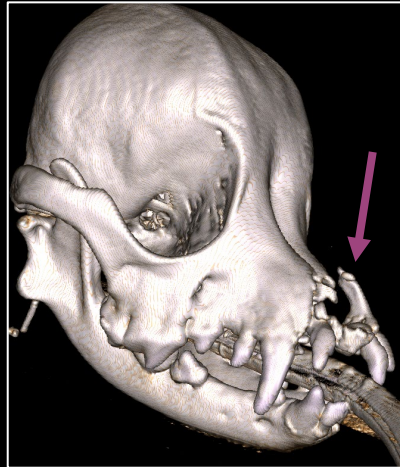
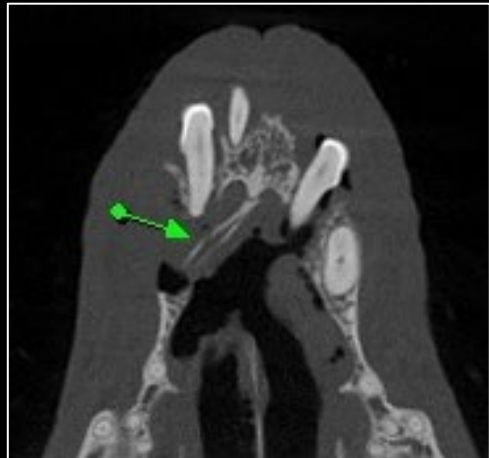

Meet precious little Maddie! She is an 8 year old Terrier mix who was on the wrong end of an altercation with a larger dog.



Because of the altercation, Maddie suffered a fractured segment of her maxilla that was not reparable, which can be seen in the image (below).

With the help of high-quality images of **VetCAT CBCT**, Dr. Ringen was able to precisely locate and remove the painful fractured segment (below).



Thanks to Dr. Ringen and the **VetCAT CT**, Maddie's vet was able to quickly diagnose and treat her fractured maxilla.

Thanks to Davin Ringen, DVM, MS – Animal Dental Care & Oral Surgery – CO Springs, CO

Xoran is passionate about helping animals and supporting veterinarians